

Original Article

Herpes Zoster In Teenagers: Case Report

Flora Ramona Sigit Prakoeswa ¹, Hindun Luthfia Rosyida ²

¹ Faculty of Medicine of University Muhammadiyah Surakarta, Central Java, Indonesia

ARTICLE INFO

ABSTRACT

Article History

Submit : Dec 8, 2023
 Revised : Dec 24, 2023
 Accepted : Dec 27, 2023

Keywords:


Herpes Zoster
 Infection
 Teenagers

Background: Herpes Zoster (HZ) is a reactivation of the Varicella Zoster Virus (VZV), which is characterized by an acute unilateral vesicular eruption grouped with radicular pain around the dermatome. The incidence of HZ increases with age and is rare in children. The prevalence of HZ in children can occur if they have a history of primary intrauterine infection, are immunocompromised, and are infected with varicella in the first year of life.

Methods: The research design used a case study on one of the patients at the PKU Muhammadiyah Hospital Surakarta Polyclinic. The instruments include informed consent and demographic data questionnaires.


Results: Ms B, 15 years old, came to the Skin and Venereology Clinic, PKU Muhammadiyah Surakarta Hospital on December 28, 2022 with complaints of itching and heat, a lesion in the form of multiple clustered vesicles, round in shape, with a size of 0.3- 0.5 cm above the skin, erythematous, unilateral, not crossing the midline, the age of the cysts in one group is the same. Still, with other groups, it is not the same; the skin between groups is normal. Treatment was given acyclovir 4x800 mg per day taken orally for five days, triamcinolone 4 mg/day, compressed NaCl 15 minutes 2x daily, calamine lotion 2x daily on intact lesions and mupirocin calcium on open wounds.

Conclusion: Maintaining the body's immune system and managing stress, as well as getting the varicella vaccine/measles vaccine, can prevent the occurrence of shingles

 Corresponding Author

 Affiliation

 Email

 Cite this as

: Flora Ramona Sigit Prakoeswa
 : Faculty of Medicine of University Muhammadiyah Surakarta, Central Java, Indonesia
 : flora.ramona@ums.ac.id
 : Prakoeswa, F. R. S. ., & Rosyida, H. L. . (2023). Herpes Zoster In Teenagers: Case Report. Journal of Applied Nursing and Health, 5(2), 355-360. <https://doi.org/10.55018/janh.v5i2.167>

Introduction

Herpes zoster (HZ) is a reactivation disease of the Varicella Zoster virus in patients who have previously been infected. Blisters characterise this disease in a dermatome of the spinal or cranial ganglia, where the virus is dormant, and intense radicular pain in the lesion area—the incidence of herpes zoster increases in direct proportion to increasing age. Reactivation occurs if the body's immune

system decreases. The characteristics of this disease are characterised by the presence of a unilateral vesicular rash in groups with radicular pain around the dermatome. Varicella is a primary infection that occurs first in individuals who come into contact with the varicella-zoster virus. Varicella zoster experiences reactivation, causing recurrent infections known as Herpes zoster. The prevalence of shingles is not



influenced by race, gender, or season. The incidence of this disease increases with age and is rarely found in children. Herpes zoster can occur in children who have a history of primary intrauterine infection, immunocompromised conditions, and who were infected with varicella in the first year of life. ([Shiraki et al., 2021](#)).

The incidence of herpes zoster increases with age and is usually rare in children. In the United States, more than 1 million cases of herpes zoster occur each year, and more than 90 per cent of adults have serologic evidence of varicella-zoster virus infection and are at risk of developing herpes zoster. The incidence of herpes zoster is around 3-4 cases per 1000 people. People who are over 85 years old and do not receive vaccinations have a 50% risk of suffering from shingles, and 3% of patients require hospital treatment. The incidence of shingles increases dramatically with age, and approximately 30% of the population (1 in 3 people) will experience shingles during their lifetime. Reactivation of the varicella-zoster virus can be triggered by various factors such as surgery, radiation, old age, and a weak body condition, including malnutrition, someone who is on long-term immunosuppressant treatment, or suffering from a systemic disease such as hypertension. ([Patil et al., 2022](#)).

Herpes zoster usually begins with prodromal symptoms, such as pain, itching or tingling in the lesion area for several days or weeks, allodynia or pain due to light touch, before a rash appears or the rash may not appear, known as zoster sine herpette. Other symptoms, such as headache, malaise, and photophobia, may occur. Apart from pruritus of the lesion, the main complaint of about 75% of patients is pain, burning, throbbing or stabbing. Symptoms may resemble pain caused by ischemic heart disease, cholecystitis or renal colic. 7 Supporting examinations for herpes zoster

include the Tzank test, skin biopsy, viral culture, fluorescent antibody, serological test, and polymerase chain reaction (PCR). 1-3 Herpes zoster in immunocompetent children can heal on its own, so the management given is only supportive. However, specific therapy can be considered in certain cases ([Rosmalia Dewi & Isti Anggraini, 2020](#)).

Methods

The research design used a case study on one of the patients at the PKU Muhammadiyah Hospital Surakarta Polyclinic. The instruments include informed consent and demographic data questionnaires.

Results

A woman, Ms B, 15 years old, as a santri or boarding school student, came to the Skin and Venereology Clinic of PKU Muhammadiyah Hospital Surakarta on December 28 2022 with complaints of small nodules that had gathered together filled with water with a reddish base since two days ago on the left back of the back and there were also a nodule with a reddish base the size of a pin under the left armpit. Patients complain of these nodules, feeling pain like being stabbed, hot, sore and itchy. One week ago, the patient complained that his body felt hot, not too high, persistent, and not accompanied by shivering—difficulty sleeping and decreased appetite in the last two days due to increasingly severe body pain. The patient also admitted that the complaint felt worse during activity but also did not get better when resting. The patient did not complain of any skin complaints in other areas, nor did he complain of vision or hearing problems.

The patient denied that he had suffered from smallpox before, but after the researchers conducted an alloanamnesis with the family, the patient's mother

admitted that her child had experienced measles at the age of 6 months. The patient is a student at an Islamic boarding school who is far away and rarely interacts with his family. Before the fever, the patient admitted that he had an irregular sleep rhythm because he had to organise organisations and prepare for exams for junior high school graduation requirements; because of this, his sleep time had only been 4 hours/day for the last month. The patient denies any drug allergies. The patient denies that there is a

family history of diabetes mellitus and hypertension.

Investigations supporting herpes zoster in this case, such as antigen/nucleic acid identification examination using the PCR method and the Tzank test in the vesicle eruption phase, were not carried out because the results of the anamnesis and physical examination, including UKK and Predilection, were sufficient to confirm the diagnosis of Herpes Zoster. ([Leung et al., 2022](#)).

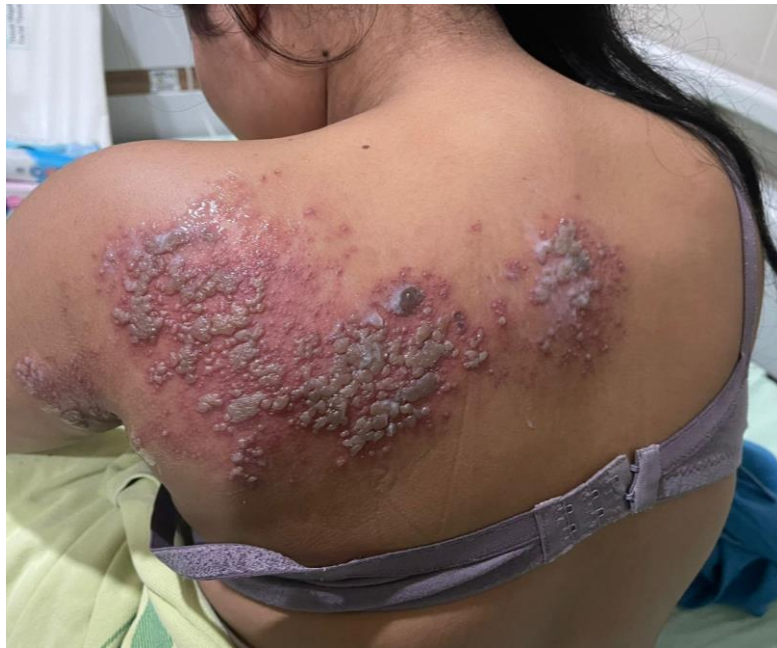

Figure 1. Dorsal view. On the upper left back at the level of T2-T6, small vesicles clustered in multiple round shapes measuring 0.3-0.5 cm above the erythematous skin, unilateral, not crossing the midline (picture of the first day of treatment)

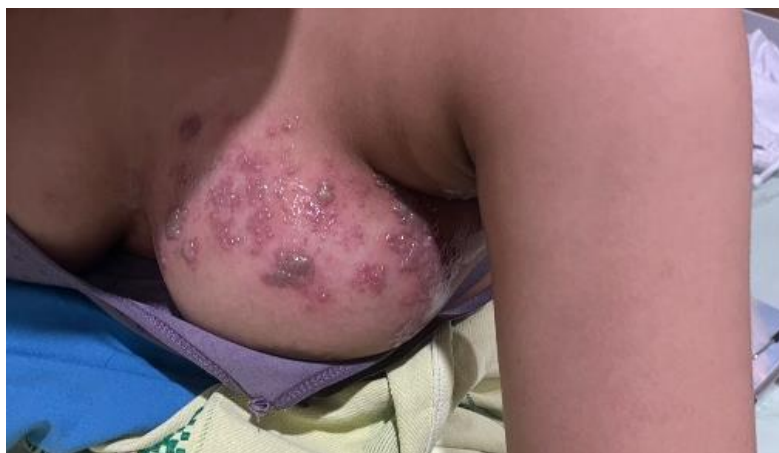

Figure 2. Ventral view, on the left chest, small vesicles clustered in multiple round shapes measuring 0.3-0.5 cm above the erythematous skin, unilateral, not crossing the midline (picture of the first day of treatment)

Pharmacological therapy for herpes zoster is acyclovir 4x800 mg per day taken orally for five days, triamcinolone 4 mg/day, NaCl compresses 15 minutes 2x a day, calamine lotion 2x a day on intact lesions and mupirocin calcium on open wounds. The patient was recommended for hospitalisation to facilitate treatment and to observe complications of herpes zoster in the form of dermatovenerological neuralgia and joint treatment with a neurologist. In integrated treatment, the patient also received gabapentin 300 mg/day for four weeks, paracetamol 3x500 mg/day and methylprednisolone injection 125 mg/8 hours, as well as changing oral acyclovir to IV acyclovir 20 mg/kg BW/day four times a day for five days. Acyclovir is dissolved in 100 cc of 0.9% NaCl and given within 1 hour.

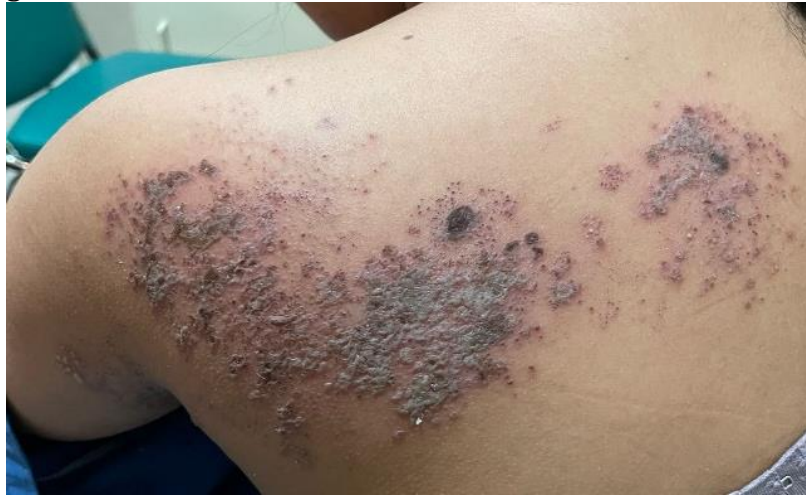

Figure 3. Dorsal view. Lesions after treatment day 4

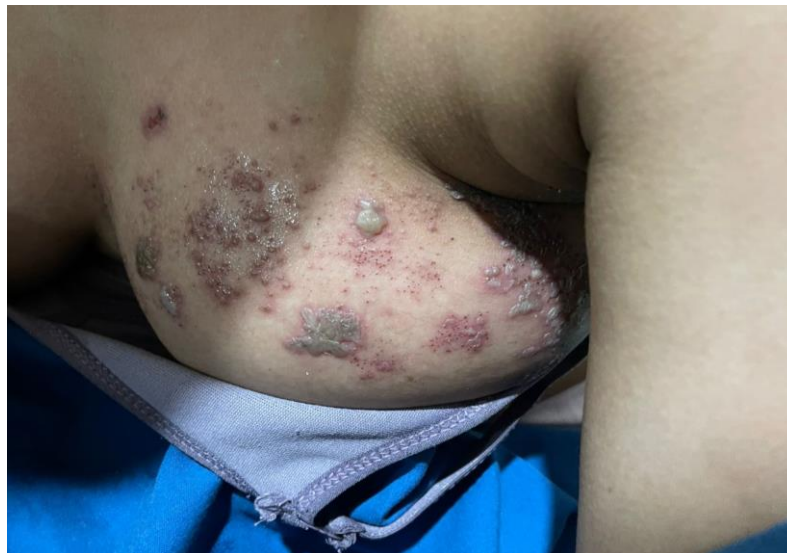

Figure 4. Ventral view. Lesions after the fourth day of treatment

Discussion

The diagnosis of Herpes Zoster can be made by taking anamnesis, physical examination and supporting examinations if necessary. Ms. B, a patient, came to the

Skin. Venereology Clinic of PKU Muhammadiyah Hospital Surakarta with complaints: Small pustules have appeared that have gathered together and filled with water with a reddish base since two days

ago. They have been left back. There is also a nodule with a reddish base the size of a pin under the left armpit. From the results of the anamnesis carried out using auto anamnesis and alloanamnesis, the patient said since one week ago, the patient complained that his body felt hot, not too high, persistent, and not accompanied by shivering—difficulty sleeping and decreased appetite in the last two days due to increasingly severe body pain. The patient also admitted that the complaint felt worse during activity but also did not get better when resting. The patient did not complain of any skin complaints in other areas, nor did he complain of vision or hearing problems.

Before complaints of fever appeared, the patient admitted that he had an irregular sleep rhythm because he had to organise organisations and prepare for exams for junior high school graduation requirements; because of this, he had only slept 4 hours/day for the last month. The patient denies any drug allergies. From the previous medical history, the researcher conducted an alloanamnesis with the patient's mother, the patient's mother admitted that her child had been exposed to measles when he was six months old.

Based on the results of the patient's history of being exposed to measles / Varicella Zoster Virus at the age of 6 months or early in life, this is in line with the risk factors for shingles under the age of 50 years. Alternatively, in children who have a history of primary intrauterine infection, immunocompromised conditions, and who were infected with varicella in the first year of life ([Rafferty et al., 2021](#)).

The diagnosis of herpes zoster is generally based on the clinical picture with the diagnosis confirmed by the presence of prodromal symptoms in the form of pain, a typical dermatomal distribution, the

presence of grouped vesicles or in some cases papules, several groups of lesions filling the dermatome, especially where there are sensory nerves, no history of similar rashes. In the same distribution (excluding herpes simplex zosteriformis), pain and allodynia (pain that occurs with stimuli that normally do not cause pain) in the area of the rash. Herpes zoster usually begins with prodromal symptoms for 2-4 days, namely systemic (fever, dizziness, malaise), and local (muscle-bone pain, itching, aches). After that, erythema will appear which turns into grouped vesicles with an edematous and erythematous skin base. These vesicles contain clear fluid, then become cloudy and can become pustules and crusts. The Varicella Zoster virus initiates Herpes Zoster. Where the budding period of this virus is around 7-12 days; the active period, in the form of new lesions that continue to appear, lasts a week, and the resolution period lasts 1-2 weeks ([Leung et al., 2022](#)).

In this case, the treatment for shingles is given antivirals in the form of acyclovir, corticosteroids in the form of triamcinolone to reduce inflammation, NaCl compresses to relieve pain (analgesics); apart from that, NaCl has an anti-inflammatory effect and reduces oedema through the process of osmosis.

Caladin lotion containing calamine, zinc oxide, and diphenhydramine HCl, as an anti-irritant and as a topical antihistamine, is given to closed lesions because the zinc oxide is able to form a layer so that it does not rub easily and get worse—Mupirocin is an antibiotic for ruptured vesicles to prevent infection ([Devi et al., 2022](#)).

To facilitate integrated care, patients are advised to be hospitalised; for this reason, oral acyclovir is changed to intravenous, and triamcinolone is changed to IV methylprednisolone. In integrated treatment, patients also receive neuralgia

medication in the form of gabapentin which has antispasmodic and muscle relaxant effects to treat neuropathic pain and paracetamol as a systemic analgesic and antipyretic. The prognosis in this patient is *quo ad vitam*: Bonam, *quo ad functional*: Dubai ad Bonam, *quo ad sensational*: Bonam (Patil et al., 2022).

Conclusion

A 15-year-old girl diagnosed with herpes zoster had a history of being infected with varicella zoster when she was six months old. In this case, immunodeficiency triggers repeated infections of varicella zoster, which causes Herpes Zoster. Maintaining the body's immune system and managing stress, as well as getting the varicella vaccine/measles vaccine, can prevent the occurrence of shingles (Koide & Nishigaki, 2022).

Authors Contributions

The author carries out tasks from data collection, data analysis, and discussions to making manuscripts.

Conflicts of Interest

There is no conflict of interest.

Acknowledgment

Thank you to the respondents and to those who have helped in this research

References

- Devi, M., Ismunandar, H., & Wintoko, R. (2022). Diagnosis and Management of Herpes Zoster. *Medula*, 12, 40.
- Koide, T., & Nishigaki, T. (2022). A Case of Herpes Zoster Due to Varicella-Zoster Virus Vaccines in a 14-Month-old Girl. *Pediatric Infectious Disease Journal*, 41(10), 860–861. <https://doi.org/10.1097/INF.0000000000003638>

- Leung, J., Dooling, K., Marin, M., Anderson, T. C., & Harpaz, R. (2022). The Impact of Universal Varicella Vaccination on Herpes Zoster Incidence in the United States: Comparison of Birth Cohorts Preceding and Following Varicella Vaccination Program Launch. *Journal of Infectious Diseases*, 226, S470–S477. <https://doi.org/10.1093/infdis/jiac255>
- Patil, A., Goldust, M., & Wollina, U. (2022). Herpes zoster: A Review of Clinical Manifestations and Management. In *Viruses* (Vol. 14, Issue 2). MDPI. <https://doi.org/10.3390/v14020192>
- Rafferty, E., Reifferscheid, L., Russell, M. L., Booth, S., Svenson, L. W., & MacDonald, S. E. (2021). The impact of varicella vaccination on paediatric herpes zoster epidemiology: a Canadian population-based retrospective cohort study. *European Journal of Clinical Microbiology and Infectious Diseases*, 40(11), 2363–2370. <https://doi.org/10.1007/s10096-021-04298-z>
- Rosmalia Dewi, N., & Isti Anggraini, D. (2020). Holistic Management of Shingles on 15 Years Old Adolescent Boy Through Family Medicine Approach. *Medula*.
- Shiraki, K., Toyama, N., Tanaka, K., Ito, A., & Yamamoto, J. (2021). Effect of universal varicella vaccination and behavioral changes against coronavirus disease 2019 pandemic on the incidence of herpes zoster. *Journal of Dermatological Science*, 104(3), 185–192. <https://doi.org/10.1016/j.jdermsci.2021.10.007>